

Multicenter Long Term Experience with Management of TASC II C, D Femoropopliteal Occlusive Disease Drug Coated Versus Uncoated Ballon Angioplasty

Mohammad Alsagheer Alhewy^{1,*}, Abdelaziz Ahmed Abdelhafez², Ehab Abdelmoneim Ghazala¹

¹Departments of Vascular Surgery, Faculty of Medicine, Al-Azhar University, Assiut, Egypt

²Departments of Vascular Surgery, Faculty of Medicine, Al-Azhar University, Cairo, Egypt

Email address:

elsagher2030@yahoo.com (M. A. Alhewy)

*Corresponding author

To cite this article:

Mohammad Alsagheer Alhewy, Abdelaziz Ahmed Abdelhafez, Ehab Abdelmoneim Ghazala. Multicenter Long Term Experience with Management of TASC II C, D Femoropopliteal Occlusive Disease Drug Coated Versus Uncoated Ballon Angioplasty. *Cardiology and Cardiovascular Research*. Vol. 5, No. 4, 2021, pp. 198-203. doi: 10.11648/j.ccr.20210504.17

Received: November 4, 2021; **Accepted:** November 24, 2021; **Published:** December 2, 2021

Abstract: *Background:* The use of drug-coated balloons for the treatment of TransAtlantic Inter-Society Consensus TASC-II C, D femoro-popliteal lesions has become widespread in recent years. Drug-coated balloons promise to minimize the rates of restenosis by effective delivery of antiproliferative agent (paclitaxel) directly to vessel wall without the need for a permanent implant. Reinterventions with drug coated balloons are lower and easier to perform because we leave no stent behind. *Objective:* The aim of this retrospective study was to investigate the efficacy of drug-coated balloon (DCB) and comparing it with conventional un-coated balloon (UCB) angioplasty for the treatment of femoropopliteal occlusive disease TASC II C, D in critical lower limb ischemia. *Patients and Methods:* Thirty patients were included and presented to vascular surgery department of Al-Azhar University hospitals and Sednawy hospitals in Cairo, Elaraby Specialized Hospital in Monofia and Albahah hospital in KSA with TASC II C, D femoro-popliteal lesions, distributed into two equal groups; Group I was treated with DCB for femoropopliteal lesions while group II was treated with UCB during the period from December 2017 to November 2020. Primary end point was wound healing, limb salvage or amputation. All patients were monitored with 0, 3, 6 and 12 months' serial postoperative duplex scanning surveillance. *Results:* Twenty-five patients (83%) reached the end point of healing and limb salvage (14 patients with 'DCB' technique and 11 patients with 'UCB' technique), whereas 5 patients underwent major amputations (2 with 'DCB' technique and 3 with 'UCB' technique). The early patency rate at 1 and 3 months was 93.34% in the group with 'DCB', and 89.93% in the group with 'UCB'. While the late patency rate at one year post-operatively was 88.86% in the 'DCB' group with, and 53.33% in the 'UCB' group. *Conclusion:* Both DCB and UCB were effective for treatment of femoro-popliteal occlusive disease TASC II C, D, and there was nearly no difference regarding wound healing and limb salvage while DCB appeared to be superior on UCB regarding high patency and low re-intervention rates.

Keywords: Femoropopliteal Occlusive Disease, TASC II C, D, Drug-coated Balloons, Conventional Un-coated Balloon Angioplasty

1. Introduction

Critical limb ischemia (CLI) is a severe form of peripheral arterial disease (PAD). CLI often causes disabling symptoms of pain and can lead to loss of the affected limb. It is also associated with increased risk of myocardial infarction, stroke and death from cardiovascular

disease [1]. The primary goals of treatment in patients with CLI are to relieve ischemic pain, heal ulcers, prevent limb loss, improve leg function and patient's quality of life, and prolong overall survival [1].

Treatment modalities have included risk factor optimization through life-style modifications and medications, or operative approaches using both open and

minimally invasive techniques, such as balloon angioplasty or stenting [2].

TASC II C lesions were defined as multiple stenoses or occlusions of the femoropopliteal arteries more than 15 cm [3].

TASC II D lesions were defined as chronic total occlusions of the SFA more than 20 cm and involving the popliteal artery or chronic total occlusions of the popliteal artery and proximal trifurcation vessels [3].

TASC-II recommendations advocate traditional bypass surgical therapy for the treatment of complex lesions of femoropopliteal segments. In patients unfit for surgery, endovascular therapy may be considered in long (i.e. ≥ 25 cm) femoro-popliteal lesions [4].

Endovascular treatment is an attractive alternative to open surgical procedures for peripheral arterial disease (PAD) due to its minimal invasive character. Various therapeutic strategies can be planned to treat long femoropopliteal (FP) lesions, such as self-expandable or balloon-expandable stent, drug eluting balloon or stent, or covered stent. The use of drug-eluting balloons for treatment of femoro-popliteal arterial occlusion has become widespread in recent years. The possibility to deliver a drug into the arterial wall with sustained anti-proliferative effects, without leaving behind metal stents, seems very promising with lower restenosis rates in target peripheral arteries compared with conventional treatment [5].

The use of drug-eluting balloons for treatment of femoro-popliteal artery obstructions has become widespread in recent years. Drug-coated balloons promise to reduce the occurrence of restenosis by effective delivery of antiproliferative agent (paclitaxel) directly to vessel wall without the need for a permanent implant [6].

The challenging idea behind the drug-coated balloon (DCB) concept is the biological modification of the injury response after balloon dilatation. Major advantages of the DCBs are the rapid delivery of drug at uniform concentrations with a single dose, their efficacy in areas where in stents have been contraindicated until now (bifurcation, ostial lesions), and in leaving no stent scaffold behind. Reinterventions are easier to perform because DCBs leave no metal behind [7].

The aim of this retrospective study was to investigate the efficacy of drug-coated balloon (DCB) and comparing it with conventional un-coated balloon (UCB) angioplasty for the treatment of femoropopliteal occlusive disease TASC II C, D in critical leg ischemia.

2. Patients and Methods

This prospective multicenter single blinded randomized study included *thirty* patients complaining of critical lower limb ischemia due to femoro-popliteal arterial occlusive disease. The present study conducted to vascular surgery department of Al-Azhar University hospitals and Sednawy hospitals in Cairo, Elaraby Specialized Hospital in Monofia and Albahah hospital in

KSA with TASC-II C, D femoro-popliteal lesions during the period from December 2017 to November 2020. According to treatment policy patients will be randomly divided into two groups:

- (1) *Group A*: included 15 patients with symptomatic femoro-popliteal arterial occlusive disease treated by drug coated balloon angioplasty DCB.
- (2) *Group B*: includes 15 patients with symptomatic femoro-popliteal arterial occlusive disease treated by conventional un-coated balloon (UCB) angioplasty.

2.1. Inclusion Criteria

- 1) Adults (Age over 18).
- 2) Symptomatic atherosclerotic lesions of the femoropopliteal artery TASC II C, D.
- 3) De novo lesions.
- 4) At least one patent below-the-knee artery with uninterrupted flow to the pedal arch.
- 5) Resting ankle-brachial index (ABI) < 0.5 in the study limb prior to procedure.
- 6) Signed informed consent.

2.2. Exclusion Criteria

- 1) Asymptomatic or TASC II A, B. Femoro-popliteal lesions.
- 2) Acute thrombus or aneurysm in the target vessel.
- 3) Previous endovascular or surgical treatment of the target femoropopliteal artery.
- 4) Inflow lesions that cannot be successfully pretreated.
- 5) Failure to cross the target lesion with a guidewire.
- 6) Significant disease of all 3 infrapopliteal vessels.
- 7) Concomitant (intentional or accidental) use of alternative therapies in the target vessel, including atherectomy, excimer laser, or cutting balloon during the index procedure.
- 8) Renal failure (serum creatinine > 2.0 mg/dL).
- 9) Known allergy to iodinated contrast agents.
- 10) Non-salvageable foot.
- 11) Contraindication to anticoagulation or antiplatelet therapy.

2.3. Ethical Approval and Written Informed Consent

An approval of the study was obtained from Al-Azhar University academic and ethical committee. Every patient signed an informed written consent for acceptance of the research.

2.4. Clinical Examination

At the initial clinical presentation full history was taken from every patient and the clinical data were prospectively collected regarding age, gender, risk factors and comorbidities. Ankle brachial index (ABI) Laboratory including CBC, platelet count, Blood sugar level, Kidney functions, Liver functions, Coagulation profile, and radiological assessment were done including full details of

duplex scanning, including ankle peak systolic velocity APSV. Computerized topographic arteriography (CTA) and magnetic resonance angiography (MRA): especially in patients with renal insufficiency.

3. Procedure

Every case was studied individually and according to the mentioned criteria it was subjected to percutaneous angioplasty using either the drug coated or the conventional uncoated balloons as a primary choice. The procedure was done in the angio-suite in Elaraby Specialized Hospital in Monofia or in the operation room Al-Azhar University and Sednawy hospitals in Cairo and Assiut under complete aseptic technique, and mobile C arm with vascular imaging capabilities. We used non-ionic contrast medium (*ultravist*). At the end of each procedure the details of technique were documented individually regarding:

- 1) *Anaesthesia*: local, regional or general.
- 2) *Site of arterial puncture*.
- 3) Contra- or ipsi-lateral femoral access was used as the lesions were in femoropopliteal segments.
- 4) *Duration of the procedure*.
- 5) *Equipment used*.
 - (1) sheath (Fr) size;
 - (2) Guide wire type;
 - (3) Balloon type Size (diameter and length);
 - (4) Guiding catheters used;
 - (5) Pressure used;
 - (6) Lesions were categorized as stenoses, occlusions, or both.

3.1. Post Procedural

Therapeutic low molecular weight heparin (LMWH) anticoagulation was given for 48 hrs and Clopidogril 75 mg/day for 12 weeks as well as Asprin 100 mg / day indefinitely.

Patients were followed up until they reached one of the end points of the study, which were wound healing, limb salvage or amputation.

During follow-up, data were collected regarding wound status, the details of the management plan, details of duplex scanning including APSV, ABI.

3.2. Statistical Methodology

Data were collected, revised, coded and analyzed using statistical package for social science (IBM SPSS) version 23.

3.3. Descriptive Statistics

The quantitative data were presented as number (No.), percentage (%), mean (X), and standard deviation (SD) were determined. The comparison between two independent groups with quantitative data and parametric distribution was done by using One Way Analysis of Variance (ANOVA). Significance level (P) value: P value <0.05 was considered significant (S).

4. Results

The study included 30 patients, (22 males and 8 females) with a mean age 59.9 (± 13.68). All patients were diabetic. The demographic characteristics and risk factor distribution are shown in Table 1.

Table 1. Baseline clinical characteristics of the patients.

Parameters	Patients	No.	Percent (%)
Gender	Male	22	73%
	Female	8	27%
	Mean \pm SD	59.9 (± 13.68)	
Age (year)	Min.	50	
	Max.	87	
Ischemic heart disease	Negative	10	33%
	Positive	20	67%
Hypertension (HTN)	Negative	15	50%
	Positive	15	50%
Diabetes	Negative	0	0
	Positive	30	100

- 1) Technical success occurred in 22 of patients (73%) "12 with 'DCB' technique and 10 with 'UCB' technique" showing <30% residual stenosis in 13 patients as optimal technical success and between 30-50% residual stenosis in 9 patients as suboptimal result. While 8/30 UCB (27%) was technically failed: 4 with 'DCB' technique and 4 with 'UCB' technique.
- 2) Technical complications occurred in 12 patients (40%): Four of them (13.3%) developed arterial spasm six patients (20%) developed groin haematoma, 3 of them (10%) developed flow limiting dissection and another one developed thrombosis.
- 3) Wound healing and limb salvage after one year was 83% (25 patients): (14 patients with 'DCB' technique and 11 patients with 'UCB' technique) and 17% (5 patients) underwent major amputations (2 with 'DB' technique and 3 with 'PB' technique), are shown in Figure 1.

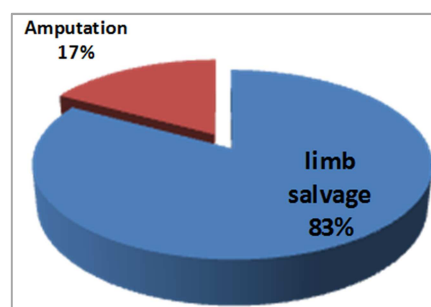


Figure 1. Results of limb salvage and amputation in the studied patients.

The early patency rate at 1 and 3 months was 93.34% in the group with 'DCB', and 89.93% in the group with 'PTA'. While the late patency rate at one year post-operatively was 88.86% in the 'DCB' group with, and 53.33% in the 'UCB' group.

Recurrence and re-intervention rates after one year were of less than 27% (8 patients) with 'DCB' technique and 37% (11 patients) with 'UCB' technique.

The average means APSV of the 25 limbs with healed or

adequately healing lesions was significantly higher than that of the 5 limbs with non-healing lesions: 57.86 cm/s (± 12.72) versus 24.90 cm/s (± 9.55), $p < 0.001$, shown in figure 2.

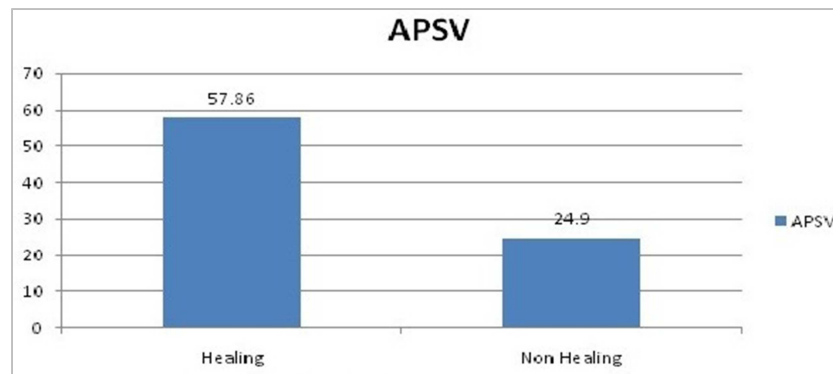


Figure 2. Correlation between APSV and healing, at a value of 57.86 cm/sec (± 12.72) the patient healed

While, at a value of 24.91 cm/sec (± 9.55) the patient neither healed nor showed any progression of healing.

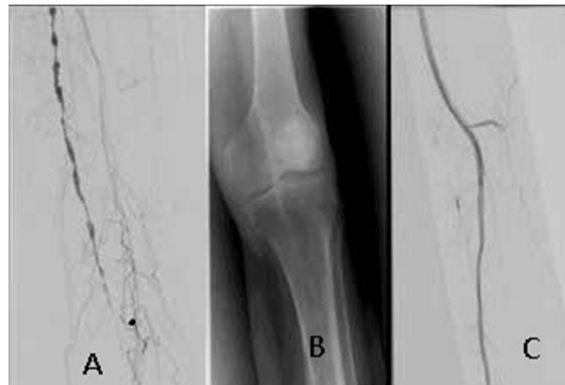

Figure 3. An example of revascularization of the LT femoropopliteal arteries. (A) Baseline angiogram shows TASC-II C femoro-popliteal multiple stenotic lesions of 58-year-old CLI female patient. (B) Drug-coated balloon angioplasty was done (C) Completion angiogram showing successful recanalization.

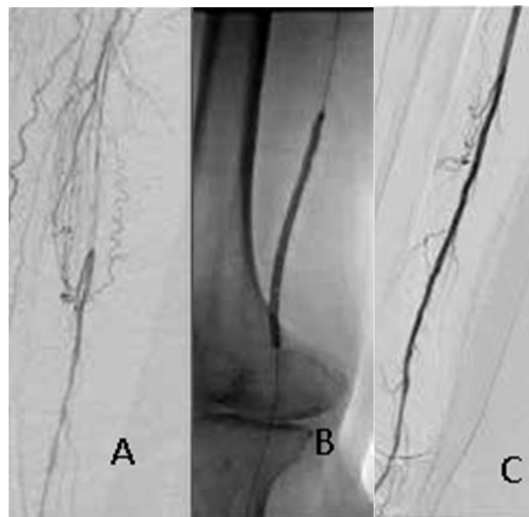


Figure 4. An example of revascularization of the RT femoropopliteal arteries. (A) Baseline angiogram showing TASC-II D chronic total long femoro-popliteal lesion of 72-year-old CLI male patient. (B) Uncoated balloon angioplasty was done (C) Completion angiogram showing successful recanalization.

5. Discussion

Endovascular treatment of symptomatic atherosclerotic PAD has gained widespread acceptance and is now

recommended as the primary revascularization strategy in many clinical and anatomic scenarios [8].

TASC-II recommendations advocate traditional bypass surgical therapy for the treatment of complex lesions of femoropopliteal segments. In patients unfit for surgery,

endovascular therapy may be considered in long (i.e. ≥ 25 cm) femoro-popliteal lesions [9].

Percutaneous transluminal angioplasty (PTA) of the superficial femoral and popliteal artery has a high initial success rate, but restenosis occurs in up to 60% of cases [10]. Although randomized trials have demonstrated patency rates with bare metal stents and drug-eluting stents superior to those observed with PTA [11], the optimal treatment for superficial femoral and popliteal artery disease remains controversial. Some practice guidelines advise against primary stenting in patients with intermittent claudication, whereas others recommend primary stenting in long lesions or in the event of acute PTA failure. Despite the improved outcomes reported in some trials with stenting, the dynamic stresses applied by the superficial femoral and popliteal artery may result in stent fracture or stent restenosis [11].

On the limitations of stenting, Drug-coated balloons (DCB) have emerged as a potential alternative in treating in-stent restenosis; however, their role in the treatment of de novo lesions is unclear [12].

Drug-coated balloons were designed to reduce stenosis, but clinical outcomes vary depending on patient characteristics, treated limbs, and the severity of the lesions. In this analysis, there were still failures with opportunities to improve the reliability of outcomes after conventional therapies. In particular, lesions that are heavily calcified or totally occluded may result in insufficient drug transfer into the vessel wall, hampering long-term anti-restenotic effects of the DCB [13]. Recently, more endovascular devices have been available. Atherectomy and specialty balloons have been designed to specifically remove plaque or alter vessel compliance, and their use prior to inflation of a DCB is hypothesized to increase uptake of the anti-restenotic drug. This could be particularly important in complex lesions to maximize the effectiveness of DCB therapy.

The extent of the use of drug-coated balloons will be driven by the limitations of other endovascular techniques. Drug-coated balloons have a number of advantages over standard angioplasty and stent technologies including: (1) the potential for homogeneous drug delivery to the vessel wall which is not accomplished using drug-eluting stents. (2) Immediate drug release without the use of a polymer that can induce chronic inflammation and late thrombosis, as observed with some drug-eluting stents. (3) The option of using balloon catheters alone or in combination with a bare-metal stent. (4) No foreign object, such as a drug-eluting stent, is left behind in the body. (5) The potential for reducing antiplatelet therapy. (6) Lower restenosis rates in target peripheral arteries compared with conventional treatment [14].

This study was to assess the efficacy of drug-coated balloon (DCB) and comparing it with conventional un-coated balloon (UCB) angioplasty for the treatment of femoropopliteal occlusive disease TASC II C, D in critical lower limb ischemia.

In our retrospective assessment 30 patients were

included with TASC II C, D femoro-popliteal lesions, distributed into two equal groups; (22 males and 8 females) with a mean age $59.9 (\pm 13.68)$. In the present study, all 30 patients were diabetics, 15 patients (50%) were suffering from hypertension (HTN), and 20 patients were with IHD (67%).

The present study agrees with the results reported by Grus that diabetes mellitus was predictive of restenosis and limb loss [15].

In the present study, the primary technical success rate was achieved in 22 patients (73% of all studied patients). "12 with 'DCB' technique and 10 with 'UCB' technique" showing $<30\%$ residual stenosis in 13 patients as optimal technical success and between 30-50% residual stenosis in 9 patients as suboptimal result. While 8/30 PTA (27%) was technically failed: 4 with 'DCB' technique and 4 with 'UCB' technique.

In the study by Stein *et al.*, the technical success was achieved in 90% (38 out of 42 patients) [16].

Wound healing and limb salvage after one year was 83% (25 patients); (14 patients with 'DCB' technique and 11 patients with 'UCB' technique) and 5 patients underwent major amputations (17%) (2 with 'DB' technique and 3 with 'PB' technique).

In the study of *Moher* limb salvage after one year was 89.7% (92 patients) while amputation rate was 10.3% [17].

Technical complications occurred in 12 patients (40%): Four of them (13.3%) developed arterial spasm six patients (20%) developed groin hematoma, 3 of them (10%) developed flow limiting dissection and another one developed thrombosis.

In the present study, the early patency rate at 1 and 3 months was 93.34% in the group with 'DCB', and 89.93% in the group with 'UCB'. While the late patency rate at one year post-operatively was 88.86% in the 'DCB' group with, and 53.33% in the 'UCB' group. Another previous study by Kabra *et al.*, showed a higher primary patency (88%) compared with this study [10]. Recurrence and re-intervention rates after one year were of less than 27% (8 patients) with 'DCB' technique and 37% (11 patients) with 'UCB' technique.

Laird reported that DCB angioplasty is technically successful in 96%–100% of cases, with few complications and recurrence rates of less than 22% [18].

The limitations of our study include its small size,

So more studies with a large numbers of patients are needed to confirm the result also we suggest exclusion of diabetic patients in a separate study to discover is there a difference in the result.

6. Conclusion

Both DCB and UCB are effective for treatment of femoropopliteal occlusive disease TASC II C, D and there is nearly no difference regarding the expected wound healing and limb salvage while DCB appears to be superior on UCB regarding high patency and low re-intervention rates.

Financial and Declarations of Interest

All the authors do not have any possible conflicts of interest.

References

- [1] Conte, MS, Bradbury, AW, Kolh, P. (2019): Global vascular guidelines on the management of chronic limb-threatening ischemia. *Eur J Vasc Endovasc Surg*; 58 (1S): S1–S109.e33.
- [2] Roh J, Young-GukKo, Chul-MinAhn *et al.* (2019): Risk Factors for Restenosis after Drug-coated Balloon Angioplasty for Complex Femoropopliteal Arterial Occlusive Disease. *annals of vasc surg*; 55: 45-54.
- [3] Norgren L, Hiatt WR, Dormandy JA, Nehler MR, Harris KA, Fowkes FG (2006); TASC II Working Group. Inter-society consensus for the management of peripheral arterial disease (TASC II). *J Vasc Surg.* 2007; 45 (suppl S): S5–67. doi: 10.1016/j.jvs.12.037.
- [4] Caradu, C, Lakhli, E, Colacchio, EC, *et al.* (2019): Systematic review and updated meta-analysis of the use of drug-coated balloon angioplasty versus plain old balloon angioplasty for femoropopliteal arterial disease. *J Vasc Surg*; 70: 981–995.e10.
- [5] Giannopoulos, S, Varcoe, RL, Lichtenberg, M, *et al.* (2020): Balloon angioplasty of infrapopliteal arteries: a systematic review and proposed algorithm for optimal endovascular therapy. *J Endovasc Ther.*; 27: 547–564.
- [6] Salisbury, AC, Li, H, Vilain, KR, *et al.* (2016): Cost-effectiveness of endovascular femoropopliteal intervention using drug-coated balloons versus standard percutaneous transluminal angioplasty: results from the IN. PACT SFA II Trial. *JACC Cardiovasc Interv*; 9: 2343–2352.
- [7] Donas, KP, Sohr, A, Pitoulas, GA, *et al.* (2020): Long-term mortality of matched patients with intermittent claudication treated by high-dose paclitaxel-coated balloon versus plain balloon angioplasty: a real-world study. *Cardiovasc Intervent Radiol.*; 43: 2–7.
- [8] Anantha-Narayanan, M, Shah, SM, Jelani, QU, *et al.* (2019) Drug-coated balloon versus plain old balloon angioplasty in femoropopliteal disease: an updated meta-analysis of randomized controlled trials. *Catheter Cardiovasc Interv.*; 94: 139–148.
- [9] Mohapatra A, Saadeddin Z Daniel J. Bertges *et al* (2020): Nationwide trends in drug-coated balloon and drug-eluting stent utilization in the femoropopliteal arteries. *J Vasc Surg*; 71: 560-566.
- [10] Roh JW, Ko YG, Ahn CM, Hong SJ, Shin DH, Kim JS, *et al.* (2019): Risk factors for restenosis after drug-coated balloon angioplasty for complex femoropopliteal arterial occlusive disease. *Ann Vasc Surg*; 55: 45–54.
- [11] S. Steiner, A. Willfort-Ehringer, H. Sievert, V. Geist, M. Lichtenberg, C. Del Giudice, *et al.* (2018): 12-Month results from the first-in-human randomized study of the Ranger paclitaxel-coated balloon for femoropopliteal treatment *JACC Cardiovasc Interv*, 11, pp. 934-941.
- [12] Klein AJ, Chen SJ, Messenger JC, Hansgen AR, Plomondon ME, Carroll JD, Casserly IP. (2019): Quantitative assessment of the conformational change in the femoropopliteal artery with leg movement. *Catheter Cardiovasc Interv.*; 74: 787–798. doi: 10.1002/ccd.22124.
- [13] Fanelli F, Cannavale A, Gazzetti M, *et al.* (2014): Calcium burden assessment and impact on drug-eluting balloons in peripheral arterial disease. *Cardiovasc Intervent Radiol.*; 37: 898-907.
- [14] Ihnat, DM, Duong, ST, Taylor, ZC (2008): Contemporary outcomes after superficial femoral artery angioplasty and stenting: the influence of TASC classification and runoff score. *J Vasc Surg*; 47: 967–974.
- [15] Grus T, Lukas L, Gabriela G, Peter L, Jan H and Jaroslav L (2017): Branched crural bypass has no advantage over simple crural bypass in the treatment of peripheral arterial disease, *Int J Clin Exp Med.*, 10 (5): 7859-7866.
- [16] Stein R, Hriljac I, Halperin JL *et al.* (2006): Limitation of the resting ankle-brachial index in symptomatic patients with peripheral arterial disease. *Vasc Med.*, 11: 29-33.
- [17] Moher D, Liberati A, Tetzlaff J, Altman DG. (2009): Preferred reporting items for systematic reviews and meta-analyses: the PRISMA statement. *Ann Intern Med.*; 151: 264–269, W64.
- [18] Laird JR, Yeo KK. (2012): The treatment of femoropopliteal in-stent restenosis: back to the future. *J Am Coll Cardiol*; 59: 24–25. doi: 10.1016/j.jacc.2011.09.037.