

Case Report

Myocardial Infarction with Non-obstructive Coronary Arteries (MINOCA): A Case Report and Review of the Literature

Jie Chen^{1,2,†}, Wenjie Liang^{3,†}, Mei Wei², Mingqi Zheng², Gang Liu^{2,*}, Guoping Ma^{2,*}

¹Graduate School of Hebei Medical University, Hebei Medical University, Shijiazhuang, China

²The First Hospital of Hebei Medical University, Shijiazhuang, China

³College of Integrated Traditional Chinese and Western Medicine, Hebei University of Chinese Medicine, Shijiazhuang, China

Email address:

chenjie1997_1013@163.com (Jie Chen), lwj712004@126.com (Wenjie Liang), mei491458@sina.com (Mei Wei),
mzheng2020@163.com (Mingqi Zheng), cardio2004@163.com (Gang Liu), mgp2006@163.com (Guoping Ma)

*Corresponding author

† Jie Chen and Wenjie Liang are co-first authors.

To cite this article:

Jie Chen, Wenjie Liang, Mei Wei, Mingqi Zheng, Gang Liu, Guoping Ma. Myocardial Infarction with Non-obstructive Coronary Arteries (MINOCA): A Case Report and Review of the Literature. *Cardiology and Cardiovascular Research*. Vol. 5, No. 3, 2021, pp. 153-156. doi: 10.11648/j.ccr.20210503.15

Received: August 19, 2021; **Accepted:** September 3, 2021; **Published:** September 15, 2021

Abstract: *Background:* About 5-10% of all myocardial infarction patients undergoing diagnostic coronary angiography for typical chest pain have no significant coronary stenosis (stenosis severity <50%). We classified these patients as myocardial infarction (MI) with non-obstructive coronary arteries (MINOCA), which is characterized by both the diagnostic criteria of myocardial infarction and no significant coronary stenosis (stenosis severity <50%). The pathophysiology of MINOCA is multifactorial. Potential underlying mechanisms of MINOCA include coronary causes such as coronary spasm, coronary microvascular dysfunction, plaque disruption, spontaneous coronary thrombosis/emboli, and coronary dissection; myocardial disorders, including myocarditis, takotsubo cardiomyopathy, and other cardiomyopathies; and noncardiac causes, for example, pulmonary embolism. Early secondary prophylaxis with drugs including statins and renin-angiotensin-aldosterone system inhibitors may be beneficial to prognosis. *Objective:* To report a case of MINOCA, analyze its clinical manifestations, imaging and related treatment, and improve the understanding of clinicians on MINOCA. *Methods:* A case of MINOCA diagnosed in the First Hospital of Hebei Medical University on June 8, 2021 was retrospectively analyzed. Clinical data related to clinical manifestations, examination results, diagnosis and treatment process were collected, and literatures related to non-obstructive myocardial infarction were reviewed to summarize its diagnosis and treatment characteristics. *Results:* The patient was a 73-year-old male, who was admitted to hospital for 8 hours due to sudden precordial pain. After admission, relevant preoperative examination was completed, and preoperative electrocardiogram (ECG) and troponin examination results were considered as acute inferior wall myocardial infarction, percutaneous coronary angiography showed no significant narrowing of the coronary vessels and was diagnosed as MINOCA. The patient regularly applied drugs outside the hospital and was generally in good condition. He did not go to the hospital again. *Conclusion:* 1. MINOCA accounts for 5-10% of all MI patients, and a higher proportion of MINOCA patients are female. 2. It was previously believed that MINOCA patients had a good prognosis, but the incidence of major adverse cardiovascular events was still high in clinical work. The pathogenesis of MINOCA is complex and diverse, and early drug intervention and secondary prevention targeting the etiology can improve the prognosis of patients. 3. The clinical manifestations and characteristics of MINOCA patients were summarized in this case, the possible pathogenesis and treatment, so as to improve the understanding of this disease, screen high-risk groups for early intervention, and reduce the risk of adverse cardiovascular events in these patients.

Keywords: Myocardial Infarction, Non-obstructive, Coronary Artery Disease, Coronary Angiography, Case Report

1. Introduction

Approximately 5-10% of all myocardial infarction patients do not have significant coronary artery stenosis [1, 4]. For these patients, the term myocardial infarction with nonobstructive coronary arteries (MINOCA) is used.

MINOCA is characterized by both the diagnostic criteria of myocardial infarction and no significant coronary stenosis (<50% stenosis) [2-4], at the time of angiography, the cause and thus a specific diagnosis for the clinical presentation is not apparent [7]. Possible mechanisms include coronary plaque rupture, thrombosis, coronary spasm, spontaneous coronary dissection, Takotsubo syndrome, etc [3, 5]. At present, there is no specific method for the etiological diagnosis of MINOCA, which mainly relies on intravascular ultrasound examination, optical coherence tomography, cardiac magnetic resonance imaging and other examinations [4, 6]. It is very important to clarify the etiology of MINOCA, which has guiding significance for early drug treatment of patients [7]. Early secondary prophylaxis with drugs including statins and renin-angiotensin-aldosterone system inhibitors may be beneficial to prognosis [8].

2. Case Report

The 73-year-old patient had a history of cerebral infarction and left impaired mobility of the left lower extremity. He had suffered from hypertension for 10 years and regularly taking dihydropyridine drugs to control his blood pressure.

Eight hours before admission, he had a sudden onset of precardiac chest pain with no obvious cause, radiating pain in his left shoulder and left upper limb, accompanied by sweating. He was admitted to the local hospital and had a temperature of 98 F, pulse rate 64/min, regular, and blood pressure of 150/86 mm Hg. Electrocardiogram (ECG) showed ST-segment elevation in leads III and aVF, with extensive front wall lead T wave inversion, with extensive front wall leads T wave inversion. After 300 mg aspirin and 300 mg clopidogrel chewing, he was transferred to our hospital.

Biologically assessment, showed troponin I was 2.2 ng/ml (higher than the 99th percentile reference upper limit), B-type brain natriuretic peptide precursor 1110 pg/ml, creatine kinase 383 U/L. The blood examination and blood lipids were not abnormal. Color echocardiography showed reduced motion of the inferior wall of the left ventricle with an ejection fraction of 59%.

He was given heparin intravenous anticoagulant therapy, and activated partial thrombin time and its ratio were monitored (1.5-3.0 times of the normal control APTT was appropriate). After anticoagulation and antiplatelet treatment, the patient's chest pain symptoms improved, troponin gradually decreased to normal, and the ECG leads did not increase again.

Coronary angiography was performed 1 week later and no significant stenosis was observed. The results were as follows, (Figure 1).

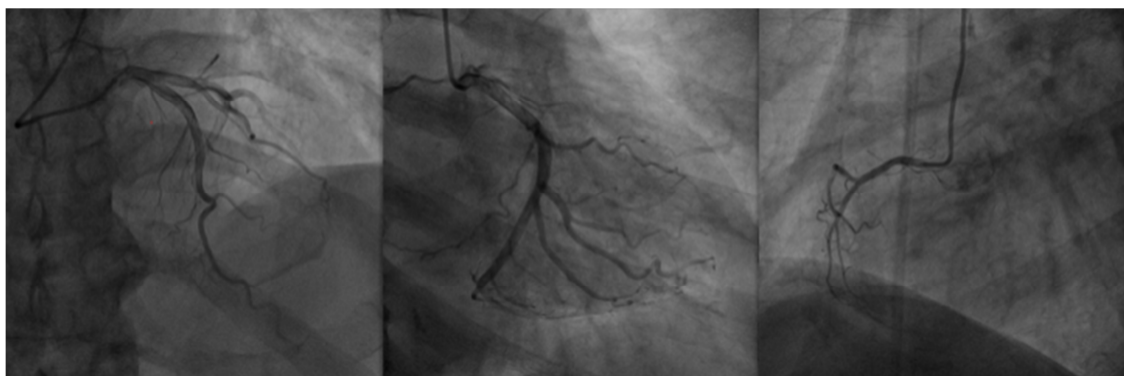


Figure 1. Percutaneous coronary angiography showing no significant coronary artery stenosis.

The patient was considered to have myocardial infarction with non-obstructive, and regular out-of-hospital drug therapy such as dual antibodies, angiotensin converting enzyme inhibitor (ACEI), statins and other drugs was applied. One month after the operation, The patient underwent cardiopulmonary exercise test to check the overall cardiopulmonary function of moderately decreased exercise, anaerobic threshold was in the normal range, and electrocardiogram exercise load test was negative. Blood lipid is controlled within the normal range. During regular follow-up, the patient suffered chest tightness and shortness of breath occasionally, and did not visit to the doctor again.

3. Discussion

The diagnosis of MINOCA should meet the diagnostic criteria of both acute myocardial infarction and non-obstructive coronary artery (Table 1), which by consensus now excludes myocarditis and Takotsubo syndrome from the final diagnosis of MINOCA [9, 10]. For such an elderly male patient with multiple risk factors of coronary heart disease, most of them are caused by coronary atherosclerosis [2, 4], which leads to lack of understanding of MINOCA in clinical work. Therefore, attention should be paid to the diagnosis and treatment of MINOCA.

Table 1. Diagnostic criteria of myocardial infarction with non-obstructive coronary arteries.

The diagnosis of MINOCA is made in patients with AMI fulfilling the following criteria:

1. AMI (modified from the 'Fourth Universal Definition of Myocardial Infarction' criteria):

1) Detection of a rise or fall in cardiac troponin with at least one value above the 99th percentile upper reference limit and

2) Corroborative clinical evidence of infarction as shown by at least one of the following:

a. Symptoms of myocardial ischaemia

b. New or presumed new significant ST-T changes or new LBBB

c. Development of pathological Q waves

d. Imaging evidence of new loss of viable myocardium or new regional wall motion abnormality in a pattern consistent with an ischaemic cause

e. Identification of a coronary thrombus by angiography or autopsy

Non-obstructive coronary arteries on angiography:

1) Defined as the absence of obstructive disease on angiography (i.e. no coronary artery stenosis $\geq 50\%$) in any major epicardial vessels. This includes patients with:

2) Normal coronary arteries (no angiographic stenosis)

3) Mild luminal irregularities (angiographic stenosis $<30\%$ stenoses)

4) Moderate coronary atherosclerotic lesions (stenoses $\geq 30\%$ but $<50\%$)

No specific alternate diagnosis for the clinical presentation:

Alternate diagnoses include, but are not limited to, non-ischaemic causes such as sepsis, pulmonary embolism, and myocarditis

In this case, the patient was male and elderly, with a history of hypertension and smoking, who was a high-risk group of coronary heart disease. He had sudden chest pain, and the ECG showed inferior wall myocardial infarction with elevated troponin, which was clinically diagnosed as acute ST-segment elevation MI. For such patients with many risk factors for coronary heart disease, it is more likely to be considered as atherosclerotic coronary heart disease [2]. After admission, the patient was given anticoagulant, statins and other drugs, and the selective coronary angiography showed no significant coronary artery stenosis, so the patient met the diagnostic criteria of MINOCA [9, 10]. The pathogenesis of MINOCA is complex and diverse, and has not been clearly defined. The possible pathogenesis has been divided into epicardium (vasospasm or unstable plaque without vascular display) or microvascular (Takotsubo, myocarditis, distal coronary microthrombus, etc.) [3, 11]. Simple diagnostic tests, such as left ventricular angiography for Takotsubo syndrome, may help confirm the diagnosis in time [12]. However, more specific tests [13, 14] are needed to uncover the less obvious cause of MINOCA. In particular, assessment of coronary vasomotor by intracoronary acetylcholine or ergotrine tests may require the exclusion of epicardial or microvascular coronary spasm [4, 11]. In this case, coronary angiography did not show plaque rupture, thrombosis and dissection, and the deficiencies were mainly limited by the examination level of our hospital and the patient's will, resulting in a lack of comprehensive diagnostic examination. It is important to clarify the etiology of MINOCA because treatment regimens are based on the underlying pathogenesis [7]. Related examinations were not completed to further clarify the cause of the patient's disease, but through this patient, the clinician broke the inertia thinking and established a new clinical thinking. Therefore, in clinical work, relevant examinations should be improved to further identify the cause, and individualized treatment plan should be formulated to achieve clinical outcomes.

Lindahl et al. [1] has provided direction for the next

treatment of patients with MINOCA in a multicenter randomized controlled trial. In this study, the potential etiology of MINOCA patients was identified through prospectively designed experiments and targeted treatment was conducted. It has been demonstrated that early agents for secondary prevention including statins and renin-angiotensin-aldosterone system inhibitors may improve outcomes in MINOCA patients. The benefit of beta blockers remained neutral, but there was no benefit from dual antibody therapy [1, 8, 15]. Paolisso et al. [15] confirmed that RAAS inhibitors were the only drugs significantly associated with a reduction in all-cause mortality and MACE. In this case, the patient was given statins and ACEI after discharge according to clinical guidelines to improve the prognosis.

Eggers et al. [8] found that a lower risk of non-obstructive myocardial infarction was associated with target range LDL levels. Therefore, low density lipoprotein level should be paid attention to during follow-up work.

4. Conclusion

At present, the proportion of patients with MINOCA confirmed by diagnostic coronary angiography during diagnosis and treatment cannot be ignored. The pathogenesis of MINOCA is diverse and complex, and its specific etiology and pathogenesis still need to be further studied and discovered. According to the clinical manifestations and existing examination methods of MINOCA patients, and excluding other diseases, the possibility of MINOCA should be considered, and related examinations such as intravascular ultrasound, optical coherence tomography, cardiac magnetic resonance imaging and coronary spasm stimulation test should be improved as much as possible to clarify endothelial function, plaque nature and other possible factors. Clinical assessment of MINOCA patients and early initiation of secondary prevention therapy may improve long-term outcomes in these patients. There are no clear guidelines for risk stratification, risk assessment, diagnosis and treatment in this population, and further research is needed.

Acknowledgements

We gratefully acknowledge the funding received from Hebei Traditional Chinese Medicine Administration Project (2020149).

References

- [1] Lindahl B, Baron T, Erlinge D, et al. Medical Therapy for Secondary Prevention and Long-Term Outcome in Patients With Myocardial Infarction With Nonobstructive Coronary Artery Disease. *Circulation*. 2017; 135 (16): 1481-1489.
- [2] Collet JP, Thiele H, Barbato E, et al. 2020 ESC Guidelines for the management of acute coronary syndromes in patients presenting without persistent ST-segment elevation. *European heart journal*. 2021; 42 (14): 1289-1367.
- [3] Niccoli G, Scalone G, Crea F. Acute myocardial infarction with no obstructive coronary atherosclerosis: mechanisms and management. *European heart journal*. 2015; 36 (8): 475-481.
- [4] Ibanez B, James S, Agewall S, et al. 2017 ESC Guidelines for the management of acute myocardial infarction in patients presenting with ST-segment elevation: The Task Force for the management of acute myocardial infarction in patients presenting with ST-segment elevation of the European Society of Cardiology (ESC). *European heart journal*. 2018; 39 (2): 119-177.
- [5] Pasupathy S, Air T, Dreyer RP, Tavella R, Beltrame JF. Systematic review of patients presenting with suspected myocardial infarction and nonobstructive coronary arteries. *Circulation*. 2015; 131 (10): 861-870.
- [6] Crea F, Niccoli G. Myocardial Infarction with Nonobstructive Coronary Atherosclerosis: The Need for Precision Medicine. *JACC Cardiovascular imaging*. 2019; 12 (11 Pt 1): 2222-2224.
- [7] Agewall S, Beltrame JF, Reynolds HR, et al. ESC working group position paper on myocardial infarction with non-obstructive coronary arteries. *European heart journal*. 2017; 38 (3): 143-153.
- [8] Eggers KM, Hadziosmanovic N, Baron T, et al. Myocardial Infarction with Nonobstructive Coronary Arteries: The Importance of Achieving Secondary Prevention Targets. *Am J Med*. 2018; 131 (5): 524-531 e526.
- [9] Thygesen K, Alpert JS, Jaffe AS, et al. Fourth Universal Definition of Myocardial Infarction (2018). *Circulation*. 2018; 138 (20): e618-e651.
- [10] Tamis-Holland JE, Jneid H, Reynolds HR, et al. Contemporary Diagnosis and Management of Patients With Myocardial Infarction in the Absence of Obstructive Coronary Artery Disease: A Scientific Statement From the American Heart Association. *Circulation*. 2019; 139 (18): e891-e908.
- [11] Montone RA, Niccoli G, Fracassi F, et al. Patients with acute myocardial infarction and non-obstructive coronary arteries: safety and prognostic relevance of invasive coronary provocative tests. *European heart journal*. 2018; 39 (2): 91-98.
- [12] Napp LC, Cammann VL, Jaguszewski M, et al. Coexistence and outcome of coronary artery disease in Takotsubo syndrome. *European heart journal*. 2020; 41 (34): 3255-3268.
- [13] Gerbaud E, Arabucki F, Nivet H, et al. OCT and CMR for the Diagnosis of Patients Presenting With MINOCA and Suspected Epicardial Causes. *JACC Cardiovascular imaging*. 2020; 13 (12): 2619-2631.
- [14] Dastidar AG, Rodrigues JCL, Johnson TW, et al. Myocardial Infarction With Nonobstructed Coronary Arteries: Impact of CMR Early After Presentation. *JACC Cardiovascular imaging*. 2017; 10 (10 Pt A): 1204-1206.
- [15] Paolisso P, Bergamaschi L, Satri G, et al. Secondary Prevention Medical Therapy and Outcomes in Patients With Myocardial Infarction With Non-Obstructive Coronary Artery Disease. *Front Pharmacol*. 2019; 10: 1606.