

Case Report

Acute Coronary Syndrome in Patient with Viral Hepatitis C: An Underdiagnosed Condition in Sub-Saharan Africa

Helles Murielle Lema, Mazou Ngou Temgoua^{*}, Ngam Mary Engonwei, Mounpou Blaise, Tonleu Carole, Mefire Aicha, Ahinaga Andre Jules, Boombhi Jerome, Menanga Alain

Department of Internal Medicine and Specialities, Faculty of Medicine and Biomedical Sciences, University of Yaounde I, Yaounde, Cameroon

Email address:

murielle.lema@gmail.com (H. M. Lema), neurotemgoua@yahoo.fr (M. N. Temgoua), ngammaryanne@yahoo.com (N. M. Engonwei),

blaisemounpou@yahoo.fr (M. Blaise), caroletonleu@yahoo.fr (T. Carole), nanechetou@gmail.com (M. Aicha),

Andy2jules@yahoo.fr (A. A. Jules), Boombhijerome@yahoo.fr (B. Jerome), amenanga@yahoo.fr (M. Alain)

^{*}Corresponding author

To cite this article:

Helles Murielle Lema, Mazou Ngou Temgoua, Ngam Mary Engonwei, Mounpou Blaise, Tonleu Carole, Mefire Aicha, Ahinaga Andre Jules, Boombhi Jerome, Menanga Alain. Acute Coronary Syndrome in Patient with Viral Hepatitis C: An Underdiagnosed Condition in Sub-Saharan Africa. *Cardiology and Cardiovascular Research*. Vol. 3, No. 1, 2019, pp. 18-21. doi: 10.11648/j.ccr.20190301.15

Received: February 9, 2019; **Accepted:** March 11, 2019; **Published:** March 26, 2019

Abstract: Viral hepatitis C (VHC) infection is associated with many systemic diseases. Amongst these, the association with ischemic heart disease is underdiagnosed in Sub-Saharan Africa context. We present a case of acute coronary syndrome in a Cameroonian patient with viral hepatitis C with low cardiovascular risk. A 75 years old female followed up for hepatocellular carcinoma secondary to VHC cirrhosis. She was admitted in the hospital for a sudden, resting, intense constrictive thoracic pain lasting more than one hour. This patient initially consulted the gastroenterologist, but secondarily the cardiologist 24 hours after the previous consultation. The initial workup showed ST segment elevation in lead V1 to V4 with Q Wave in the same territory and elevated value of Troponin I_{us} and CPKMB. Cardiac ultrasonography found akinesia in the anteroseptal and apical segments. Other biological exams showed a dyslipidemia without other cardiovascular risk factors. Despite poor financial resources, the patient was managed with Enoxaparine 8000 UI/12H, Clopidogrel 75mg/24H, Aspirine 100mg/24h, Rosuvastatine 10Mg/24h, Ramipril 2,5mg/24h and Nebivolol 2.5mg/24h, tramadol 100mg/8h, trimetazidine 35mg/12h, omeprazole 40mg/24h, molsidomine 1mg/8h. The pain disappeared 24hours after the beginning of the treatment. In sub-Saharan Africa with high burden of viral hepatitis C infection, we should consider this possibility in patients who present ischemic heart disease with lowcardiovascular risk.

Keywords: Acute Coronary Syndrome, Viral Hepatitis C, Sub-Saharan Africa

1. Introduction

Ischemic Heart Disease (IHD) is a public health problem worldwide. In developed countries, age-standardised mortality rates were reported to increase by 48% in men and 29% in women between the year 1990 to 2020 [1]. In sub-Saharan Africa (SSA) it is estimated to rise by 70% in men and 74% in women by 2030 [2]. The different mortality rate between developed countries and sub-Saharan region is mainly due to difficulties in early diagnostic and limited therapeutic resources in SSA [2]. But sometimes it is possible to reduce the incidence of IHD by reducing cardiovascular

risk factors [3]. Among them the major cardiovascular risk factors are high blood pressure, diabetes, dyslipidemia, tobacco consumption, obesity and family history [3]. These factors predispose the patient to develop atherosclerosis which could lead to decrease coronary blood flow leading to IHD [4]. To date, no single risk factor has been identified to be responsible for causing cardiovascular disease [3]. Some studies have shown that IHD can be due to viral infections. Amongst these infections, we have viral hepatitis, particularly the type C virus [5]. The possible role of an infectious agent in the development of experimental atherosclerosis in rodents was first reported more than 120 years ago [6].

Viral Hepatitis C (VHC) is a systemic disease that leads to cirrhosis and extrahepatic complications. The burden of this disease in SSA is high and a recent systematic review reported a seroprevalence of 6.5% in Cameroon [7]. Some studies suggest that Viral hepatitis C infection can increase cardiovascular risk by metabolic alterations, proinflammatory and profibrogenic status, as well as potential direct viral mechanisms but the relationship is not well established [5, 7-9]. Demonstrating the relationship between VHC and ischemic heart disease will contribute to reduce the burden of this cardiovascular disease in SSA. We reported a practical case of acute coronary syndrome in a Cameroonian patient with viral hepatitis C infection with low cardiovascular risk, suggesting a novel approach in this context.

2. Case Report

A 75 years old woman presented with severe constrictive

chest pain of sudden onset, with gradually increasing intensity, lasting more than one hour. The pain was constant and radiated to the back and left shoulder. She first consulted her gastroenterologist and spent 24 hours before cardiology evaluation. She had a past history of hepatocellular carcinoma (Child-Pugh B, BCLC A3) secondary to hepatitis C viral infection discovered two years ago. She is followed by a hepatogastroenterologist and she takes Sorafenib 200 mg twice daily. On entry, the patient was conscious with the following vital parameters: the blood pressure was 118/80mmhg, the heart rate 106 bpm, respiratory rate 24 cpm, Temperature 36.8°C, pulse oxymetry 95%, BMI: 26,3kg/m². Cardio-vascular examination was normal; she had no signs of hepatocellular insufficiency. The first resting electrocardiograph (ECG) realized 24 hours after the initial symptom showed an elevation of the ST segment in lead V1 to V4 with Q Wave (Figure 1).

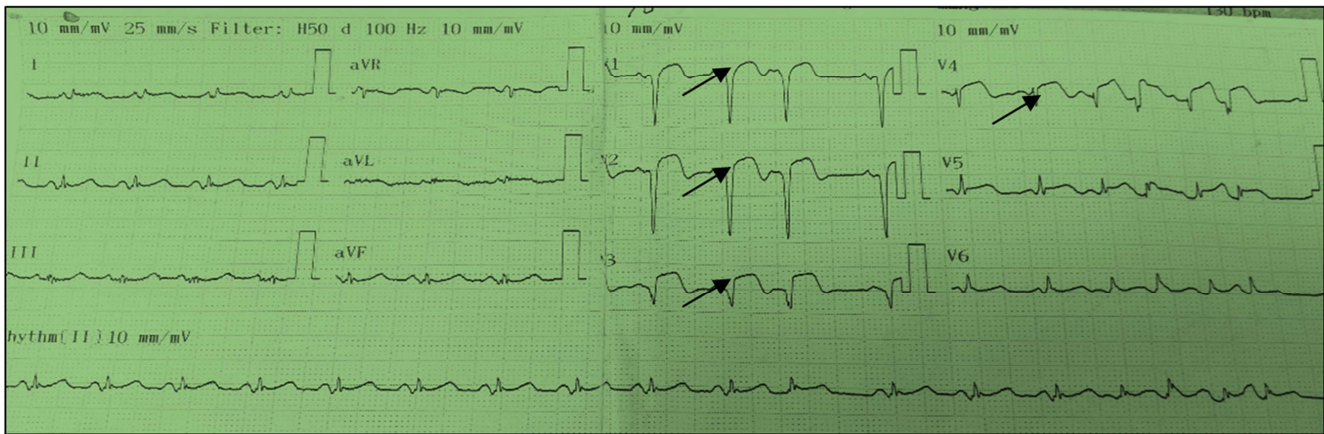


Figure 1. Significant ST elevation in V1 to V4.

Transthoracic cardiac ultrasonography showed anakinesia in the anteroseptal and apical segments with left ventriclemid-range ejection fraction at 44% (Simpson Biplane) without pericardial effusion. Biological workup revealed an elevated series of troponine I_{us} level with a pic at 2,47ng/ml (x123 the normal value) and CPK MB at 80.3 UI/l (x 3 the normal value). She had an elevated low density lipoprotein cholesterol level at 1,62g/l (N: 0,9 – 1,6 g/l) and a low high density lipoprotein cholesterol level at 0,33g/l (0,4-0,75g/l), total cholesterol, triglyceride, fasting blood glucose levels and glycated haemoglobin were normal (Table 1).

Table 1. Biological exams of the patient at the entry.

Exams	Results	Normal range
Uric acid g/l	28	30-70
Glycemia g/l	0,81	74- 110
Glycated haemoglobin %	6,1	< 7,5
HDL g/l	0,33	0,4-0,75
Total cholesterol g/l	2,14	1,4-2,7
Triglycerid g/l	0,91	0,35-1,6
LDL g/l	1,62	0,9- 1,6
CRP mg/l	24	< 6
Serum urea g/l	0,19	0,15-0,45
Serum creatinin mg/l	5,2	5- 12

Exams	Results	Normal range
ASAT UI/l	87	< 40
ALAT UI/l	48	< 40
Serum albumin g/l	43	35-50
Prothrombin level%	62,8	70-100

We were unable to perform coronary angiography to determine the specific arterial lesion due to unavailability in our setting.

We concluded to myocardial infarction with ST segment elevation at the subacute phase with no eligible criteria for thrombolytic therapy. The patient therefore received Enoxaparine 8000 UI/12H S/C, Clopidogrel 75mg/24H P.O, Aspirine 100mg/24hP.O, Rosuvastatine 10Mg/24hpo, Ramipril 2,5mg/24hpo and Nebivolol 2.5mg/24hpo, tramadol 100mg/8hpo, trimetazidine 35mg/12hpo, omeprazole 40mg/24hpo, molsidomine 1mg/8hpo. Loading doses of aspirin and clopidogrel were not given due to increased risk of bleeding. The pain disappeared 24h after the beginning of the treatment. We did daily ECG, and at day 6 of the treatment it showed a reduction of the ST segment elevation and persistent Q wave in lead V1 to V4 (Figure 2).

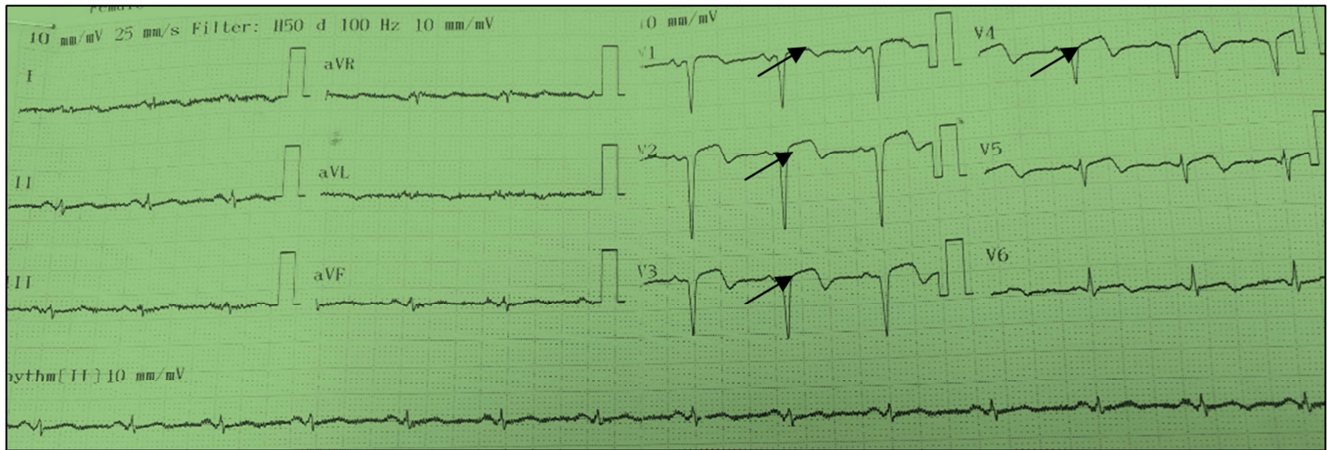


Figure 2. Control ECG at Day 6.

The control troponin I_{us} was at 0.99ng/ml (x49.5 the normal value) and CPKMB were at 61.4 UI/l (x2.4 the normal value). A possibility of secondary angioplasty was explained to the patient, but this strategy was limited by low financial resources.

3. Discussion

VHC infection is a frequent cause of cirrhosis, immuned-related disorders and metabolic alterations. Recent accumulating evidence suggests that VHC infection can increase cardiovascular risk and that viral eradication can improve cardiovascular outcomes in the clinical setting [8]. A possible association between hepatitis C and carotid atherosclerosis was firstly suggested in 1992 by Ishizaka *et al.* [10]. They conducted a cohort study of 4784 individuals in Japan and they observed that VHC seropositivity was found to be associated with an increased risk of carotid-artery plaque and carotid intima-media thickening [11]. Other studies made in Italia and Egypt also found that severe hepatic fibrosis is associated with a high risk of early carotid atherosclerosis in patients with VHC [13]. VHC seropositivity is considered to be an independent predictor for increased coronary atherosclerosis [13-15]. This can be illustrated by the presence of genomic and antigenomic VHC RNA strands within carotid plaque tissues in most VHC-infected patients [17] and by the proinflammatory and profibrogenic environment prompting fibrogenesis in the liver and in the whole cardiovascular system [13]. But these hypotheses are still debated since some authors have found normal prevalence of carotid artery plaques in patients with HVC compared with control populations [16].

This case offers the possibility to see a coronary syndrome in a patient with VHC. She was first followed up for hepatocellular carcinoma secondary to VHC cirrhosis with low cardiovascular risk factor and she came to the hospital with a typical angina pain. The initial workup constituted of resting ECG, Doppler cardiac ultrasonography troponin I_{us} and CPK-MB where in favor of an acute myocardial infarction with ST elevation. Because of limited financial resources coronary angiography was not realized to objectivate

the lesion(s). But from the localization of the ST elevation and the akinetic segment on the ultrasonography, we suppose that the stenosis must concern the anterior interventricular branch of the left coronary artery. Salam *et al.* found that the prevalence of VHC antibodies positivity in a group of Egyptians in 2014 was significantly higher in the group of patients proved angiographically to have coronary heart disease than the control group without ischemia [17]. Considering all these reasons we can strongly presume that our patient has developed ischemic events due to VHC.

4. Conclusion

VHC is an under estimated cardiovascular risk factor. Although clear relationship between this infection and ischemic heart disease is still debated, we should consider this possibility in Sub Sahara African patients who present ischemic heart disease with low cardiovascular risk.

Abbreviations

- ALAT: Alanine aminotransferase
- ASAT: Aspartate aminotransferase
- CPKMB: Creatinin phosphokinase Muscle Brain
- CRP: C reactive protein
- ECG: Electrocardiograph
- IHD: Ischemic Heart Disease
- SSA: Sub-Saharan Africa
- VHC: Viral Hepatitis C
- BCLC: Barcelona Clinic Liver Cancer
- Po: per os
- Sc: sub cutaneous

Authors' Contributions

HML, MNT, NME, MB, TE, MA, BJ, MA managed the patient. HML drafted the initial manuscript which was modified by MNT. All authors read and approved the final manuscript.

Consent for Publication

Written informed consent was obtained from the patient for publication of this case report and any accompanying images. A copy of the written consent is available for review by the Editor-in-chief of this journal.

Competing Interests

The authors declare that they have no competing interests.

References

- [1] Fabian Sanchis-Gomar, Carme Perez and al. Epidemiology of coronary heart disease and acute coronary syndrome. *Ann Transl Med.* 2016 jul; 4 (13): 256.
- [2] Lukwiga Onen CHURCHILL. Epidemiology of ischaemic heart disease in sub-saharan Africa. *Cardiovascular J Africa.* 2013; 24 (2): 34-42.
- [3] Rachel Hajar et al. Risk factors for coronaryarterydisease: historicalperspectives. *Heart views.* 2017; 18 (3): 109-114.
- [4] Libby P, Theroux p. pathophysiology of coronaryartery disease. *AHA.* 2005; 111: 3481-3488.
- [5] Obama Shoeib, Medhat Ashmawy et al. Association between coronary artery disease and hepatitis C virus seropositivity. *EMHJ-* vol. 24 N. 7-2018.
- [6] A. Gilbert and G. Lion, "Arterites infectieuses experimentales," *C R Hebd Seances Soc Biol Fil,* vol. 41, pp. 583–584, 1889.
- [7] J. Bigna, Marie Amougou et al. seroprevalence of hepatitis C virus infection in Cameroon: a systematic review and meta-analysis. *BMJ.* Vol. 7, no 8.2017.
- [8] Salvatore Petta. Hepatitis C and cardiovascular: A review. *Journal of Advanced Research* (2017) 8, 161–16.
- [9] R. Zampino, A. Marrone, L. Restivo et al., "Chronic HCV infection and inflammation: clinical impact on hepatic and extrahepatic manifestations," *World Journal of Hepatology,* vol. 5, no. 10, pp. 528–540, 2013.
- [10] N. Ishizaka, Y. Ishizaka, E. Takahashi et al., "Association between hepatitis C virus seropositivity, carotid-artery plaque and intima-media thickening," *The Lancet,* vol. 359, no. 9301, pp. 133–135, 2002.
- [11] Marwan S. Abougergi, Raffi Karagozian et al. ST Elevation Myocardial Infarction Mortality Among Patients With Liver Cirrhosis: A Nationwide Analysis Across a Decade. *J Clin Gastroenterol,* Vol. 49, no. 9, pp. 778-782, 2015.
- [12] Petta S., Torres D. et al. Carotid atherosclerosis and chronic hepatitis C: a prospective study of risk associations; *hepatology.* 2012; 55: 1317-1323. (PubMed).
- [13] Vassale C, Masini S et al. Evidence for association between hepatitis virus seropositivity and coronary artery disease. *Heart* 2004; 90: 565-566.
- [14] Alyan O, Kacmaz F et al. Hepatitis C infection is associated with increased coronary artery atherosclerosis defined by modified reardonseverity score system. *Circ J.* 2008; 72: 1960-1965.
- [15] Völzke H, Schwahn C et al. Hepatitis B and C virus infection and the risk of atherosclerosis in a general population. *Atherosclerosis* 2004; 174: 99-103.
- [16] Boddi M, Abbate R et al. HCV infection facilitates asymptomatic carotid atherosclerosis: preliminary report of HCN RNA localization in human carotid plaques. *Dig Liver Dis* 2007; 39: S55-S60.
- [17] Salam RA, Baher N et al. Prevalence of hepatitis C Virus Seropositivity and its impact on coronary artery disease among Egyptian patients referred for coronary angiography. *Cardiol Res Pract.* 2016.