

Case Report

Bicameral Pacemaker Implant in an Extremely Rare Case of Left Superior Vena Cava Anatomic Variant

Lorena Harbuz¹, Camelia Georgescu¹, Octavian Zara¹, Sergiu Sipos², Radu Ciudin³¹Department of Cardiology, "St. Ioan" Clinical Emergency Hospital, Bucharest, Romania²Department of Cardiology, Emergency Institute for Cardiovascular Diseases "Prof. CC Lliescu", Bucharest, Romania³Department of Medicine, Section of Cardiology, University of Medicine and Pharmacy "Carol Davila", Bucharest, Romania**Email address:**

lorenaharbuz@yahoo.com (L. Harbuz), camelutza_87@yahoo.com (C. Georgescu)

To cite this article:Lorena Harbuz, Camelia Georgescu, Octavian Zara, Sergiu Sipos, Radu Ciudin. Bicameral Pacemaker Implant in an Extremely Rare Case of Left Superior Vena Cava Anatomic Variant. *Cardiology and Cardiovascular Research*. Vol. 2, No. 4, 2018, pp. 91-97.

doi: 10.11648/j.ccr.20180204.14

Received: October 22, 2018; **Accepted:** November 15, 2018; **Published:** December 19, 2018

Abstract: The most common congenital venous anomaly of the thoracic systemic venous return is the persistence of the left superior vena cava (PLSVC), occurring in 0.3% to 0.5% of individuals in the general population, and in 12% of individuals with other congenital heart abnormalities. 50% of the patients with isolated PLSVC have other cardiac malformations (atrial septal defect, endocardial cushion or tetralogy of Fallot). The basis for persistence of the left superior vena cava (LSVC), usually associated with other cardiac malformations, is poorly understood. The presence of a PLSVC has a significant influence of the anatomy of the heart and venous system. There is very little in the literature that specifically addresses the potential importance of the incidental finding of PLSVC to surgeons, interventional radiologists, and other physicians actively involved in central venous access device placement. The current review is a case report of persistent left superior vena cava associated with severe disorders of intra-cardiac conduction leading to specific symptoms. This venous malformation was identified incidentally in a 80 years old patient during the procedure of pacemaker implantation. The venography showed isolated PLSVC with a bridging vein that drained the right jugular and right subclavian vein and joined the left brachiocephalic vein to form the PLSVC, which descended on the left side of the mediastinum and drained into the right atrium via a dilated coronary sinus.

Keywords: Central Venous Access, Venography, Persistent Left Superior Vena Cava, Pacemaker, Vascular Malformation, Total Atrioventricular Block

1. Introduction

Though PLSVC is the most common congenital anomaly of the thoracic systemic venous return, the exact global prevalence is unknown because the majority of the cases are asymptomatic. The prevalence of the persistent on the left side of VCS is of 0.3-0.5% in the general population [2] and 3-10% in patients with congenital heart disease. Persistent LSVC is usually asymptomatic and found incidentally during imaging study or cardiovascular procedure [17].

The data in the specialized literature are registering cases in which the right superior vena cava derives from the right anterior cardinal vein. Normally, the left anterior cardinal vein and the left part of the sinus venous are regressing. Left VCS

drains in the coronary sinus due to the persistent left anterior cardinal vein and the joint between the part of the sinus venous, which will generate the coronary sinus [1]. Ventricular size discrepancy may be due to a persistent left superior vena cava (PLSVC) in utero. Isolated PLSVC connecting to the CS is associated with differences in cardiac structure size from normal. These differences appear to diminish with gestational age. A dilated CS may have an influence on development of fetal left heart structures [12]. The basis for persistence of the left superior vena cava, usually associated with cardiac malformations, is poorly understood. Identification of a persistent left superior vena cava with coronary sinus connection should suggest an associated malformation, especially atrioventricular canal, cor

triatratrium, or mitral atresia [10]. In 80-90% of cases, the persistent left SVC is usually drains into the right atrium (in 80–92%) through a dilated coronary sinus and has no hemodynamic effect [2, 6]. The presence of left SVC is extremely rare, but one of the most important congenital vascular anomalies [6], which can be associated with other cardiac anomalies (ASD, aortic bicuspidy, aortic coarctation) [5]. The most common subtype of PLSVC results in the presence of both left and right SVC, a bridging innominate vein may or may not be present [2]. The PLSVC may drain directly through the left atrium or via the unroofed CS, which is a cause of right-to-left cardiac shunt. In general, only patients with unusual drainage and right-to-left shunting are of clinical significance. Abnormal venous return via the PLSVC may be the cause of cardiac arrhythmias, decreased exercise tolerance, progressive fatigue, chest discomfort, palpitations, syncope or cyanosis [3]. Persistent left superior vena cava is usually asymptomatic and does not cause any physiological problems. However it can severely complicate pacemaker implantation and render it sometimes impossible [16]. Access to the right side of the heart or pulmonary vasculature through the left subclavian vein is much more

difficult in patients with PLSVC [2]. Placement of a central line or cardiac resynchronization therapy leads and pacemaker implantation in undiagnosed cases with PLSVC can result in incorrect positioning. In those cases, access to the right heart and coronary sinus should be performed via the right subclavian vein, allowing for an easier route. Also the presence of PLSVC is a relative contraindication to the administration of retrograde cardioplegia during cardiac surgery [3]. When a left subclavian approach is used for vascular access, its presence can complicate catheter placement within the right side of heart. Left superior vena cava presence complicates the procedure and may result in significant extension of time needed for introduction and mounting of electrodes as well as increasing the risk of peri- and post-interventional complications [15]. This case report highlights the practical implications of PLSVC. There are multiples anatomical variants of thoracic systemic venous return (Figure 1): a) PLSVC drains into the coronary sinus and coexists with a right SVC, the left innominate vein is absent, b) PLSVC drains into the left atrium via a fenestrated coronary sinus, there is a left innominate vein, c) absence of the right SVC [1].

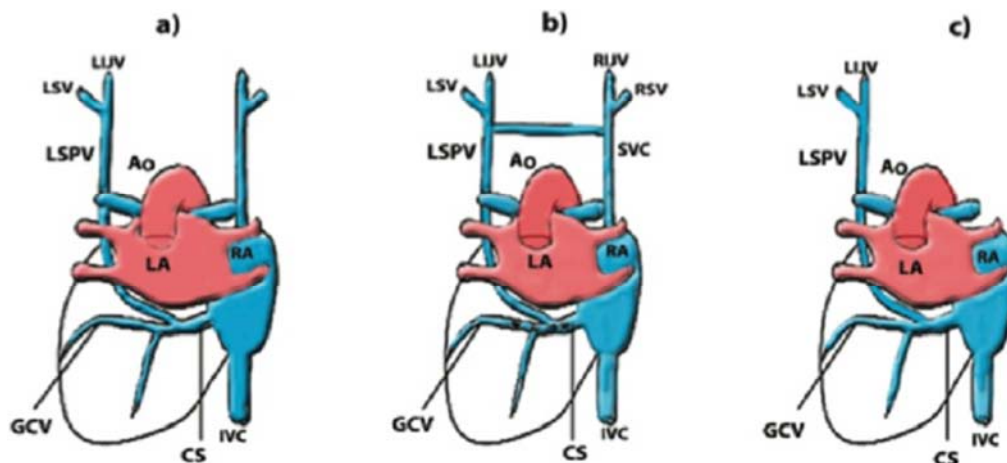


Figure 1. Anatomical variants of thoracic systemic venous return – LJV – left intern jugular vein, LSV – left subclavian vein, LSPV – left superior vena cava, Ao – aorta, LA – left atrium, RA – Right atrium, CS – coronary sinus, IVC – inferior vena cava, RIJV – right interior jugular vein, RSV – right subclavian vein, SVC – superior vena cava, GCV – great cardiac vein [1].

2. Case Report

The patient is a 80 year old male, known with cardiovascular medical history (3rd degree Essential hypertension, hypercholesterolemia, diabetes mellitus type II under treatment with oral anti diabetic drugs and 1st degree obesity). The patient came to the Emergency Department due to progressive fatigue issues.

Clinical examination showed a patient in poor general condition, overweighted. Cardiovascular exam shows: apex at left V IC space on medial clavicular line, increased cardiac dullness area, arrhythmic cardiac beats, AV 37/min, arterial tension 210/80 mmHg, without leg edema. The respirator exam is investigation is in normal limits. The rest of the clinical investigation is in normal limits.

3. Paraclinical Exams

3.1. Electrocardiogram Exam

Electrocardiogram exams were performed several times during hospitalizations. The first ECG of the patient practiced on the first day of hospitalization showed regular rhythm, total atrio ventricular block, LBBB, unspecific repolarization disorders (Figure 2). The ECG practiced at discharge showed regular sinus rhythm, BAV I, LBBB, unspecific repolarization disorders (Figure 3).

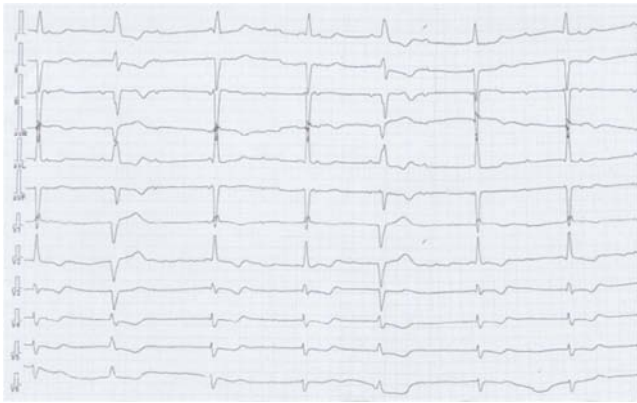


Figure 2. ECG at admission.

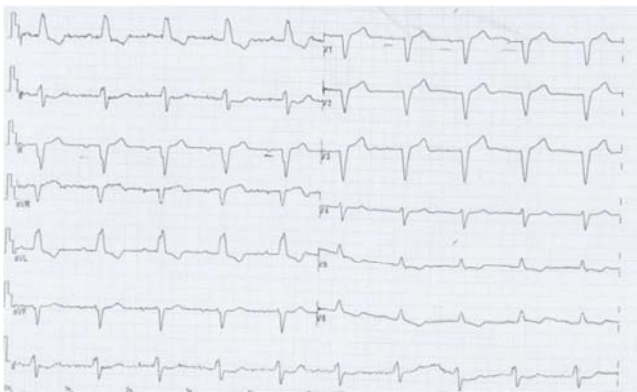

Figure 3. ECG at discharge.

3.2. Transthoracic Echocardiography

The transthoracic echocardiography was performed in 2D, parasternal long and short axis and 4-5 chambers. The conclusions were: mild left ventricular hypertrophy with a preserved systolic function (EF 55%), diastolic dysfunction type 1, the right ventricle was normal, both LA and RA were normal. The Doppler imaging showed us a mild mitral regurgitation in degenerative context with calcification of the posterior mitral ring, tricuspid valve with calcifications and moderate regurgitations, no pulmonary artery hypertension, no pericardial effusion (Figure 3, Figure 4).

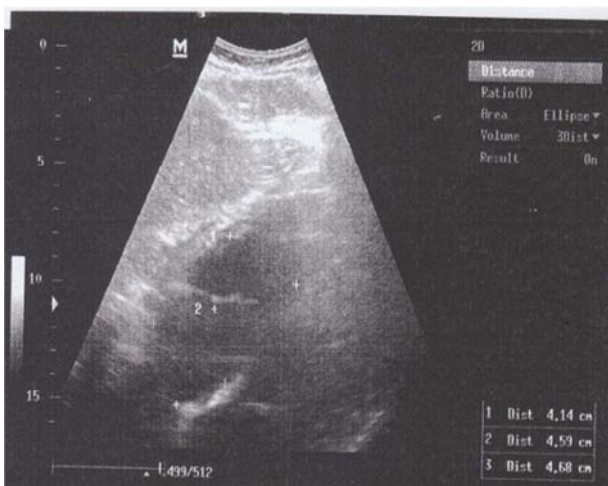


Figure 4. TEE.

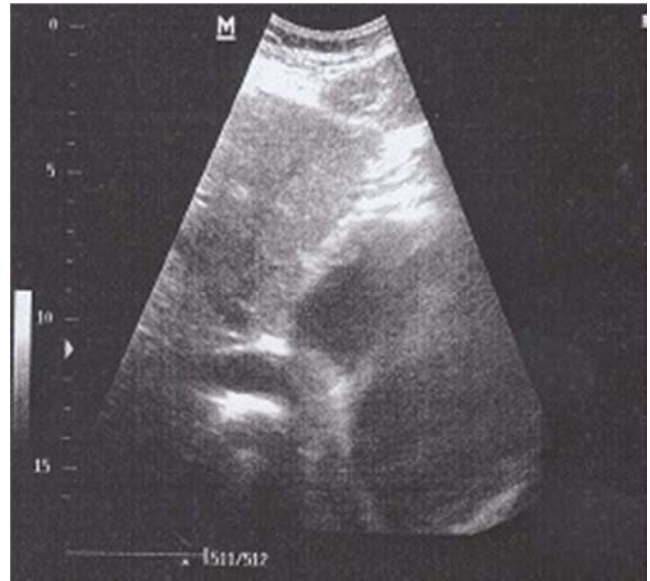


Figure 5. TEE.

4. Initial Tentative Procedure of Pacing

After all the paraclinical exams were performed, the patient was subsequently recommended for implantation of a bicameral pacemaker. Therefore, the patient was taken to the operating room by the interventional cardiologist. The right side was selected and an local anesthesia is performed with 1% Lidocaine for an approach through the right subclavian vein, the guide is introduced and it was noted on real-time intraoperative fluoroscopy of the thoracic region that the single lumen silicone catheter advanced downward in a cranio-caudal fashion along the left parameastinal border. A new approach on the left site of the patient was chosen, the left subclavian vein was found and the fluoroscopy confirmed the same pathway as on the right side (Figure 6).

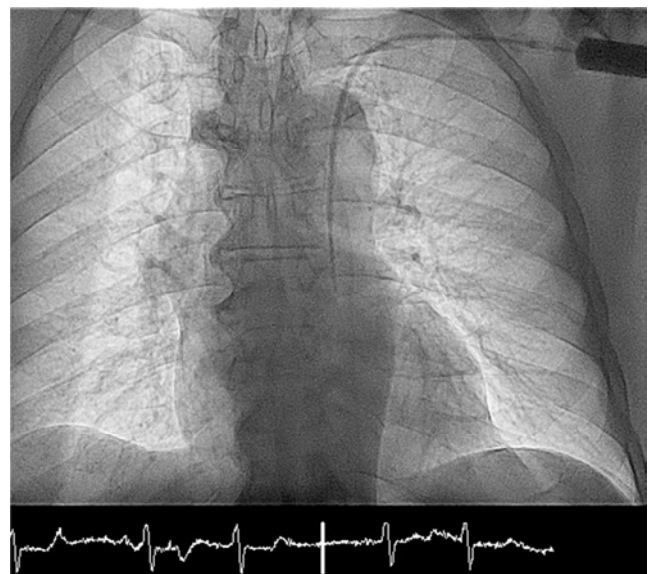

Figure 6. Intraoperative fluoroscopy of the thoracic region - single lumen silicone catheter advanced downward in a cranio-caudal fashion along the left parameastinal border.

4.1. Digital Subtraction Venography of the Left-Sided Central Venous System

As a result of this finding, intraoperative standard digital subtraction venography was undertaken subsequent in the left and right subclavian veins (Figure 7, Figure 8) and confirmed this relatively large diameter craniocaudally-oriented venous structure coursing downwards on the left side of the midline in the medial left hemi-thorax region in a location adjacent to the cardiomedastinal silhouette and which appeared to eventually drain into the cardiac silhouette, suspected by the interventional cardiologist to represent a PLSVC. The procedure is subsequently interrupted and the completion of the angiographic examination using a CT angiography is decided. On chest X-ray, PLSVC can be seen as a widened shadow of the aorta with a visible venous half-moon shadow from the left side of the aortic arch to the middle of the left clavicle.

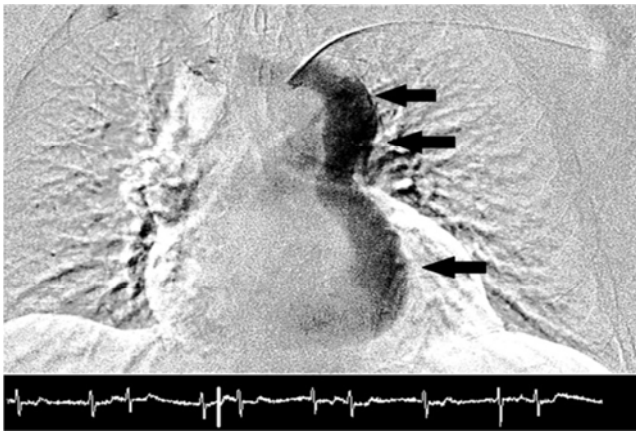


Figure 7. Intraoperative standard digital subtraction venography undertaken in the left subclavian vein, from top to bottom on the left side of the heart is the left SVC, the RA and the RV.

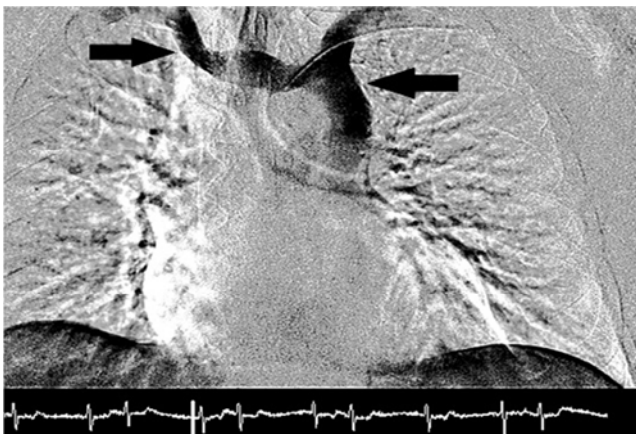


Figure 8. Intraoperative standard digital subtraction venography undertaken in the right subclavian vein, on the right side of the heart is the right subclavian vein and on the left side the left SVC. A bridging vein drains the right jugular and subclavian veins, which the join the left brachiocephalic vein to form the persistent SVC.

4.2. CT Angiography with Contrast Substance (Figure 9, Figure 10, Figure 11, Figure 12, Figure 13)

The brachial - cephalic venous truncus is joining on the left

paramedian mediastinal side, the right brachial - cephalic venous truncus is crossing the mediastinum anterior to the aortic arch. The superior vena cava is generated lateral on the left side of the aortic arch and has afterwards a descendent tract, lateral left to the left pulmonary artery and after that posterior, lateral left to the auricular and the left atrium and opens at the level of the right atrium through a coronary sinus with high volume (2.1 cm diameter). The superior vena cava situated on the right side is not evidenced. The pulmonary artery and its branches have a normal aspect. The pulmonary veins are opening in the left atrium. Conclusions: building variant of the system venous cave - superior vena cava situated on left side.

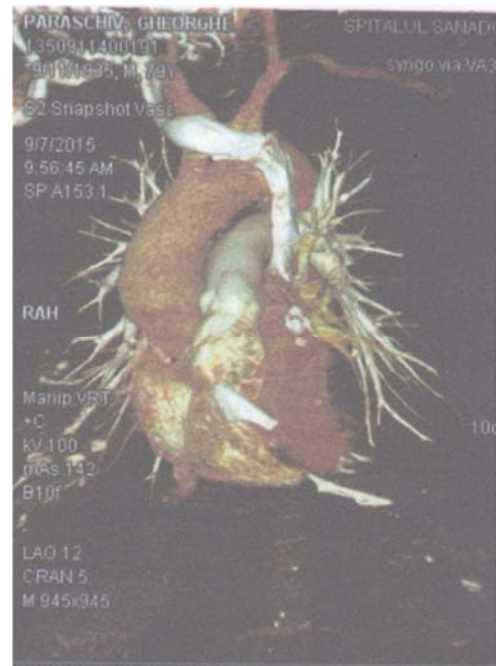


Figure 9. CT angiography.

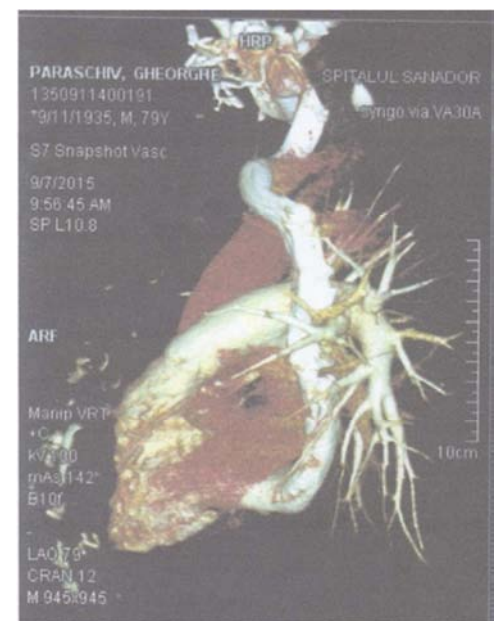


Figure 10. CT angiography.

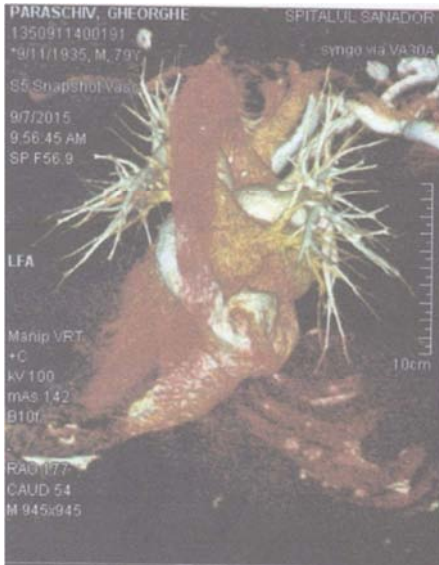


Figure 11. CT angiography.

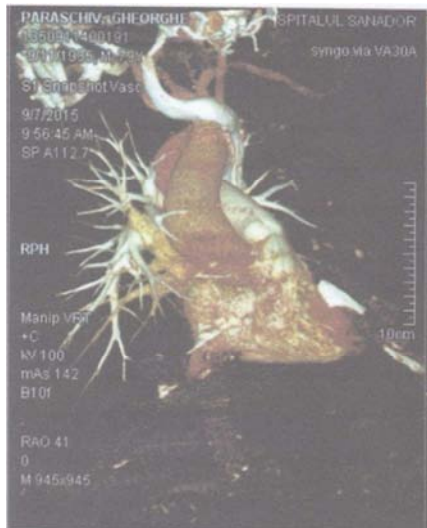


Figure 12. CT angiography.

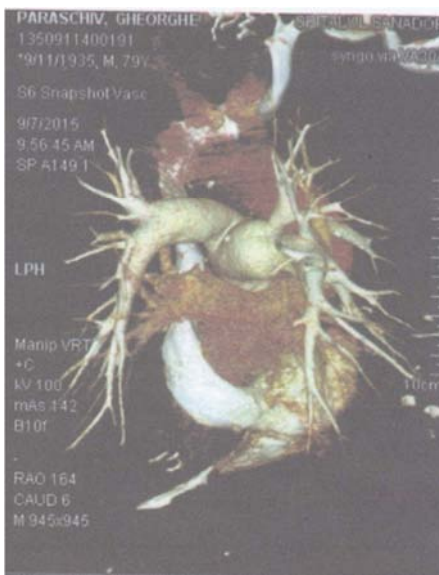


Figure 13. CT angiography.

5. Evolution

During the first hospitalization, the 3rd degree atrio-ventricular block was getting into remission under oral medication and the patient ECG at discharge showed 1st degree atrio-ventricular block with LBBB. The patient is hemodynamic stable and asymptomatic. He was discharged under oral medication with bronchodilators, calcium channel blockers, ACE inhibitors, loop diuretics and oral antidiabetics drugs. Afterwards he came at a control 6 month later, the ECG showed sinus and regulate rhythm with 1st degree atrio-ventricular block, LBBB, diffuse repolarization disorders. The patient is clinically and hemodinamically stable (BP 130/80 mmHg, HR 75/min), remaining further in clinical surveillance.

6. Bicameral Pacemaker Implantation

The patient was admitted to the Cardiology Clinic of "St. Ioan" Clinical Emergency Hospital, 6 month later after the last control, presenting severe dyspnea, the ECG exam showed 3rd degree atrio-ventricular block and the urgent implantation of a bicameral pacemaker is decided, this procedure was performed at "Prof. CC Iliescu" Emergency Institute for Cardiovascular Diseases. The local anesthesia was performed with 1% Lidocaine and the incision was made on the left side of the patient, in the left subclavian area, approach at the level of the left cephalic vein, positioning of coronary sinus tube at the level of the inferior basal wall of the right ventricle (limit 0.5V, impedance 810 Ohm - during the implantation), RA tube bipolar activated at the level of the PL (limit 1.5V, impedance 540 Ohm - during the implantation), suture of the tube with unabsorbable surgery thread, suture under cutaneous layer with absorbable surgery thread, suture between derma with absorbable surgery thread. At the end of the implantation, the final parameters are DDD 50 beats/min, A = 380 Ohm, V = 490 Ohm, VP 99%, AP 2.4%, AS-VP, E AV/VP = 150/130 msec. A ECG was performed after the procedure (Figure 14).

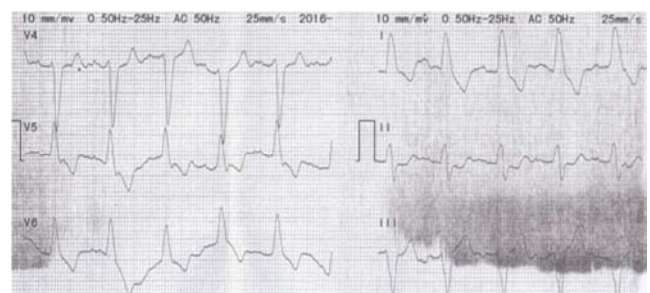


Figure 14. ECG post procedure.

X-Rays control after implantation

A subsequent postero-anterior chest X-ray (Figure 15) was performed and demonstrated the implanted left-sided bicameral pacemaker with 2 leads.

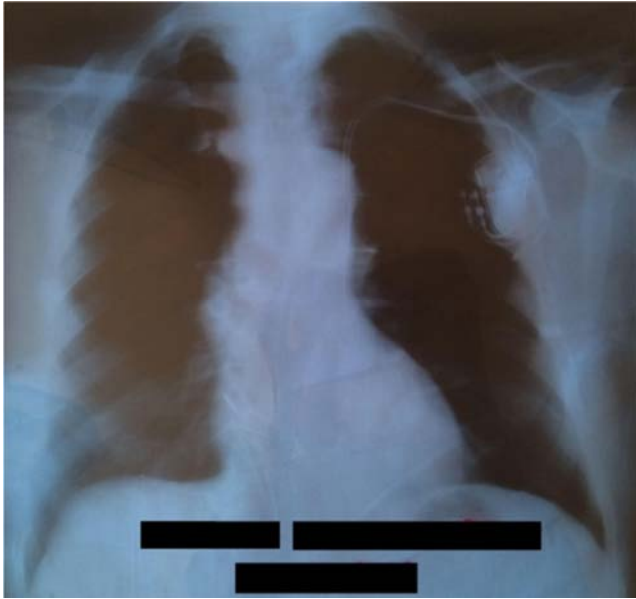

Figure 15. Chest X-ray.

7. Discussions

The particularity of this present clinical case consists in the fact that the appearance of the 3rd degree atrio-ventricular block at a patient with the mentioned cardiovascular risk factors and coronary history has allowed the establishing of a rare anatomic variant of the SVC during the procedure of implantation of a bicameral pacemaker. The vascular anomalies of the thoracic venous system return described in the specialty literature are underlining: the persistence of two superior vena cava (right and left), the presence of the left SVC associated with the absence of the right SVC or the flowing of the right SVC in the left SVC [5], anomaly found in the presented clinical case. Isolated PLSVC is usually asymptomatic but it can cause difficulties with central venous access, pace maker implantation and cardiothoracic surgery [11]. During the procedure, having in view the vascular tract, which is prolonged due to the cardiomegaly and the existence of the left SVC, a 78 cm long coronary sinus type tube has been used, with passive fixation. Due to the enlarged coronary sinus, approaching from another angle the RA, performing of a loop at the level of the RA has been necessary for a trans tricuspid fixation in the right ventricle. In the presented case the approach has been performed on the left side, the majority of the cases allowing the approach on the right side. After placing a bicameral pacemaker at a patient with PLSVC the possible complications that can appear could be severe arrhythmia, cardiogenic shock, cardiac tamponade or even SC thrombosis.

8. Conclusions

The exact origin of the first description of PLSVC remain a matter of much great debate within the historical scientific literature, although it appears to have likely occurred at some time during the 17th century to 18th century. Some have

accredited the recognition of the first description of PLSVC to the work of various individuals during that time period, including the Danish physician Thomas Bartholin (1616-1680), the English surgeon William Cheselden (1688-1752), the French surgeon Claude-Nicolas Le Cat (1700-1768), the Swiss physician Albrecht von Haller (1708-1777), the German physician Philipp Adolf Boehmer (1711-1789), and the Swedish surgeon Adolph Murray (1750-1803). However, the first in-depth review on the topic of the great anterior veins of the thoracic region, including PLSVC, in man and mammals, was published in 1850 by John Marshall (1818-1891), an English surgeon and teacher of anatomy at University College Hospital in London [4].

The PLSVC is a congenital anomaly cause by the failure of the left anterior cardinal vein to regress during the first 2 months of fetal development [13]. If a PLSVC is suspected at the time of attempted central venous access device placement, then it is essential for that patient to undergo subsequent appropriate investigations to fully characterize their central venous anatomy. This is important in order to confirm the presence of PLSVC, to characterize the central venous anatomy of the contralateral right side, to characterize the pattern of cardiac venous return to the right atrium or to the left atrium, and to evaluate the patient for other potential coexisting congenital heart abnormalities. Multiple venous imaging modalities can be utilized, as well as used in concert with one another, to accomplish complete characterization of the central venous anatomy. These venous imaging modalities include conventional contrast venography, transthoracic echocardiography, transesophageal echocardiography, multidetector computed tomography venography, and magnetic resonance venography. Conventional contrast venography can be performed in the operating room (most commonly available by using single-image, non-digital subtraction intraoperative fluoroscopy techniques and less commonly available by digital subtraction intraoperative venography) or in the interventional radiology suite (generally always available by digital subtraction venography). Although diagnosis is not very complicated, the anomaly often remains unnoticed, especially when it is clinically inaudible [6]. PLSVC is very often discovered accidentally during invasive cardiac procedures [6], mostly during routine left-sided right-heart catheterization, surgical procedures or insertion of a venous central line [8]. The most common variant of this anomaly is as follows; the PLSVC drains into the right atrium with a right superior vena cava present, which usually does not cause significant hemodynamic changes and clinical consequences. However, if the PLSVC drains into the left atrium, right-to-left cardiac shunt with desaturation and cyanosis as a consequence, is observed. The latter case often needs surgical intervention [8,9]. The venography often shows isolated PLSVC with a bridging vein that drains the right jugular and right subclavian vein and joins the left brachiocephalic vein to form the PLSVC, which descendent on the left side of the mediastinum and drains into the right atrium via a dilated coronary sinus [7].

The long-term outcome of patients with persistent LSVC

and implanted cardiac devices is mostly influenced by the presence of underlying heart disease [14].

References

- [1] Antonio Navarrete, Louis Janeira, Indiana University Health; Ablation of a Left-Sided WPW in a Patient with Total Upper Venous Return through a Persistent Left Superior Vena; Issue number: volume 13, issue 2, February 2013, www.eplabdigest.com.
- [2] Sandeep K Goyal, Sujeeth R Punnam, Gita Verma and Frederick I Ruberg; Persistent left superior vena cava: a case report and review of literature – Cardiovascular Ultrasound 2008.
- [3] Kamil W Tyrak, Mateusz K Hołda, Mateusz Koziej, Katarzyna Piątek, and Wiesława Klimek-Piotrowska, Persistent left superior vena cava, Cardiovasc Journal of Africa. 2017 May-Jun; 28(3): e1–e4. doi: 10.5830/CVJA-2016-084.
- [4] Povoski SP. Persistent left superior vena cava: review of the literature, clinical implications, and relevance of alterations in thoracic central venous anatomy as pertaining to the general principles of central venous access device placement and venography in cancer patients. *World J Surg Oncol.* 2011; 9: 173–173.[PubMed]
- [5] Lenox CC, Zuberbuhler JR, Park SC, Neches WH, Mathews RA, Fricker FJ. et al. Absent right superior vena cava with persistent left superior vena cava: implications and management. *Am J Cardiol.* 1980; 45(1): 117–122. [PubMed]
- [6] Sarodia BD, Stoller JK. Persistent left superior vena cava: case report and literature review. *Respir Care.* 2000; 45(4):411–416. [PubMed]
- [7] Ozgul Ucar, Hulya Cicekcioglu, Ibrahim Kocaoglu, Sinan Aydogdu, Lale Pasaoglu, Murat Vural, Persistent left superior vena cava with absent right superior vena cava: a case report and review of the literature, *Cardiovasc J Afr.* 2010 Jun; 21(3): 164–166.
- [8] luckianow G, Cole D, Kaplan L. Anatomical variant found during catheter insertion. *J Am Acad Phys Assist.* 2009; 22(9):60–63. [PubMed]
- [9] Rubenfire M, Evangelista J, Wajszczuk WJ, Kantrowitz A. Implication of a persistent left superior vena cava in transvenous pacemaker therapy and cardiac hemodynamic monitoring. *Chest.* 1974; 65:145–147. [PubMed]
- [10] Nsah EN1, Moore GW, Hutchins GM. Pathogenesis of persistent left superior vena cava with a coronary sinus connection. *Pediatr Pathol.* 1991Mar-Apr; 11(2):261-9.
- [11] Uçar O1, Pasaoglu L, Çiçekçioglu H, Vural M, Kocaoglu I, Aydogdu S. Persistent left superior vena cava with absent right superior vena cava: a case report and review of the literature. *Cardiovasc J Afr.* 2010 May-Jun; 21(3):164-6.
- [12] Liu X1, He Y2, Tian Z3, Rychik J3. Persistent Left Superior Vena Cava Connected to the Coronary Sinus in the Fetus: Effects on Cardiac Structure and Flow Dynamics. *Pediatr Cardiol.* 2016 Aug; 37(6):1085-90. Epub 2016 Apr 15.
- [13] Elison B1, Evans D2, Zanders T1, Jeanmonod R1. Persistent left superior vena cava draining into the pulmonary venous system discovered after central venous catheter placement. *Am J Emerg Med.* 2014 Aug; 32(8): 943.e1-3. Epub 2013 Dec 27.
- [14] Petrac D1, Radeljic V1, Pavlovic N1, Manola S1, Delic-Brkljacic D1. Persistent Left Superior Vena Cava in Patients Undergoing Cardiac Device Implantation: Clinical and Long-Term Data. *Cardiol Res.* 2013 Apr; 4(2):64-67. Epub 2013 May 9.
- [15] Anna Żabówka, Jakub Kotarba, Zbigniew Siudak, and Dariusz Dudek. Single and dual chamber pacemaker implantation in patients with left superior vena cava persistence – own experiences. *Postepy Kardiologii Interwencyjnej.* 2017; 13(2): 170–172.
- [16] Meijboom WB1, Vanderheyden M. Biventricular pacing and persistent left superior vena cava. Case report and review of the literature. *Acta Cardiol.* 2002 Aug; 57(4):287-90.
- [17] Hyun Jeong Lee, Namoo Kim, Hyelin Lee; Persistent Left Superior Vena Cava Detected Incidentally after Pulmonary Artery Catheterization. *Acute Crit Care.* 2015;30(1):22-26, www.accjournal.org.